

What Do You Mean by Aortic Valve Area: Geometric Orifice Area, Effective Orifice Area, or Gorlin Area?

Damien Garcia, Lyes Kadem

Laboratory of Biomedical Engineering, Institut de Recherches Cliniques de Montréal, Montreal, QC, Canada

Aortic valve area can be measured by cardiac catheterization, Doppler echocardiography, or imaging planimetry to assess aortic stenosis severity. These diagnostic techniques provide the Gorlin area, the effective orifice area (EOA) and the geometric orifice area (GOA), respectively. The differences between these three parameters depend mainly on the valve inflow shape and cross-sectional area of the ascending aorta. Because the values obtained may differ noticeably in the same patient, they may lead to different estimations of stenosis severity depending on the measurement method used. It is therefore essential to be aware of the underlying fundamentals on which these parameters are based. The aim of this state-of-the-art report was to clarify these hemodynamic concepts and to underline their clinical impli-

Aortic stenosis, which refers to narrowing of the aortic valve aperture during left ventricular ejection, has become the most frequent valvular heart disease and the most frequent cardiovascular disease after hypertension and coronary artery disease in Europe and North America (1). The presence of a significant aortic stenosis induces an obstruction to transvalvular blood flow that leads to a subsequent increase in left ventricular afterload. The aortic valve area (AVA) must be reduced to roughly one-fourth its normal size before any significant changes occur in hemodynamics (2). Because the adult normal AVA is 3.0-4.0 cm², an aortic stenosis is thus considered significant when its area is less than ~1 cm². AVA can be measured using either Doppler echocardiography (Fig. 1A), with the continuity equation, or by cardiac catheterization (Fig. 1B), with the Gorlin formula (3,4). Planimetry of the aortic valve orifice has recently been proposed as another

alternative for estimating AVA (Fig. 1C), and clinical application of this approach has expanded rapidly. Planimetry can be performed using transthoracic echocardiography, transesophageal echocardiography, cardiac magnetic resonance imaging, or the more recently developed multislice computed tomography (5-10). The latter technique provides the geometric orifice area (GOA) that is, the anatomical area of the aortic valve orifice. In comparison, Doppler echocardiography measures the so-called effective orifice area (EOA), which represents the minimal cross-sectional area of the flow jet downstream of the aortic valve (Fig. 2). The ratio of EOA to GOA is termed the contraction coefficient (C_c); this has been shown to be highly dependent upon the valve inflow shape, and may be as low as 0.7 in some patients with aortic stenosis (11,12). Although initially it was believed that the catheter-derived Gorlin formula provided a correct estimate of EOA, more recent studies have shown the Gorlin area to depend not only on the EOA but also on the aortic cross-sectional area (A_A) (13-15). When the term AVA is used in the literature, it is often unclear whether this refers to the GOA, the EOA, or to the Gorlin area. Because the values of these three parameters may dif-

The Journal of Heart Valve Disease 2006;15:601-608

ferences. Because planimetry only provides GOA and does not characterize the flow property, this method should preferably not be used to assess stenosis severity. The most appropriate parameters for this purpose are the Gorlin area and the energy loss coefficient (E_LCo), which corresponds to the EOA adjusted for aortic cross-sectional area. From a hemodynamic viewpoint, Doppler E_LCo and Gorlin area both reflect the fluid energy loss induced by aortic stenosis, and describe better the increased overload imposed on the left ventricle. Although the Gorlin area and Doppler E_LCo are equivalent, the latter parameter has the advantage of being measurable non-invasively using Doppler echocardiography.

Address for correspondence:

Drs. Damien Garcia/Lyes Kadem, Laboratory of Biomedical Engineering, IRCM, 110 Pine W Avenue, H2W 1R7, Montreal, QC, Canada

e-mail: Damien.Garcia@ircm.qc.ca/Lyes.Kadem@ircm.qc.ca

Doppler echocardiography
⇒ EOA

catheterization
⇒ Gorlin area

CMR planimetry
⇒ GOA

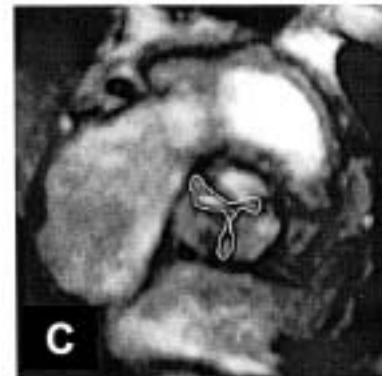
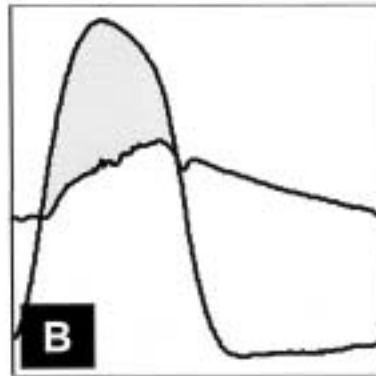
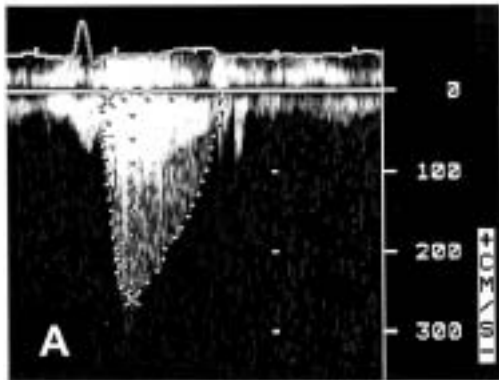


Figure 1: Different methods used to estimate aortic valve area. A) Continuity equation using Doppler echocardiography. B) Gorlin formula using catheterization. C) Planimetry using cardiac magnetic resonance. (Image C reproduced from John et al. (7), with permission.)

fer substantially in the same patient, it is important to be aware of the underlying theoretical concepts on which they are based. Hence, the aim of this state-of-the-art report was to clarify these fundamental hemodynamic concepts and underline their clinical implications.

Description of flow through an aortic stenosis

During left ventricular ejection, as the blood flow passes through an aortic stenosis, a jet is produced (Fig. 2). The blood accelerates from the left ventricular outflow tract (LVOT) as far downstream as the vena contracta, which corresponds to the location where the cross-sectional area of the jet is minimal. This area is the so-called EOA. In comparison, the GOA refers to the area of the valve opening, as measured by planimetry (Fig. 3). As the flow accelerates due to the abrupt contraction induced by the stenosis, static pressure decreases because a part of the potential energy is converted to kinetic energy. This process is stable and does not induce any significant loss in total flow energy. The difference between LVOT pressure and vena contracta pressure is the maximal transvalvular pressure gradient (TPG_{max} ; see Fig. 2). Beyond the vena contracta, the blood decelerates and the jet rapidly vanishes in a region of turbulent mixing in which part of the flow energy is irreversibly dissipated. In this deceleration area, the static pressure increases until it reaches a maximum beyond the location where reattachment of the flow occurs. Because part of the energy is lost during flow expansion, the mean downstream pressure (aortic pressure) is smaller than the mean upstream pressure (LVOT pressure). The difference between

LVOT pressure and the recovered aortic pressure is the so-called net transvalvular pressure gradient (TPG_{net} ; see Fig. 2). Two coefficients are commonly used to characterize the flow contraction in the presence of aortic stenosis, namely the discharge coefficient (C_D) and the contraction coefficient (C_C), although in the clinical literature confusion exists regarding these two coefficients. The following section provides a

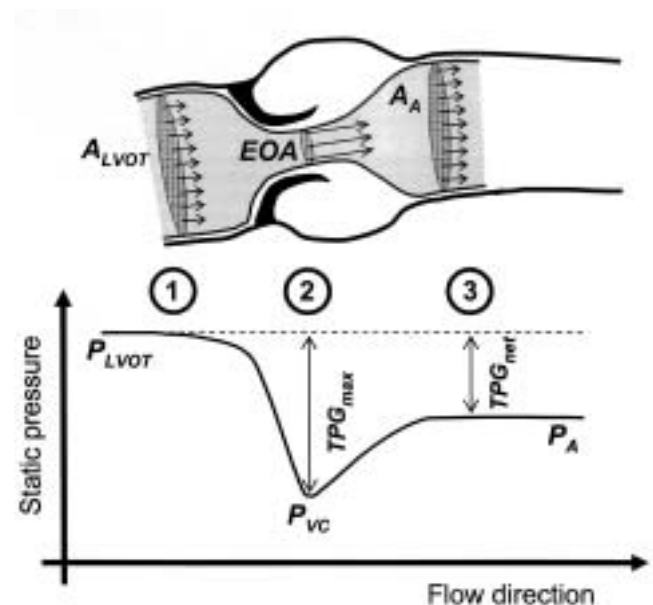


Figure 2: Schema of the systolic flow through an aortic stenosis. A_A : Aortic cross-sectional area; A_{LVOT} : LVOT cross-sectional area; EOA: Effective orifice area; P_A : Aortic pressure; P_{LVOT} : LVOT pressure; P_{VC} : Pressure at the vena contracta; TPG_{max} : Maximal transvalvular pressure gradient ($= P_{LVOT} - P_{VC}$); TPG_{net} : Net transvalvular pressure gradient ($= P_{LVOT} - P_A$).

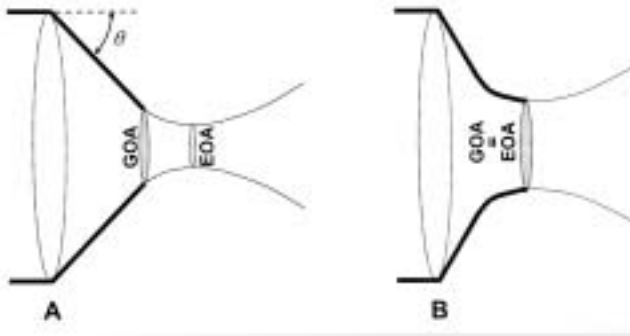


Figure 3: Definition of effective orifice area (EOA) in comparison with geometric orifice area (GOA) with: A) a rigid sharp-edged aortic stenosis; B) a funnel-shaped aortic stenosis. The angle θ represents the valvular aperture angle.

description of the respective hemodynamic properties of these coefficients before describing the different aspects of the AVA.

C_D versus C_C

The term "discharge coefficient" is often inappropriately used in place of 'contraction coefficient'. The discharge coefficient (C_D) is defined as the ratio of actual flow to ideal flow (i.e., flow without vena contracta) through an orifice. It is therefore expressed by:

$$C_D = (\text{actual flow})/(\text{ideal flow}) = Q_{\text{actual}}/Q_{\text{ideal}} \quad (1)$$

In contrast, the contraction coefficient (C_C) is defined as the ratio of the area measured at the vena contracta of a jet issuing from an orifice (EOA), to the area of the orifice (GOA) (Fig. 3):

$$C_C = \text{EOA}/\text{GOA} \quad (2)$$

The relationship between C_D and C_C can be deduced analytically using the following theoretical steps. The expression of the actual flow rate (Q_{actual}) can be written from Eqn. (1) as follows (17):

$$Q_{\text{actual}} = C_D Q_{\text{ideal}} = C_D \text{GOA} \sqrt{\frac{2 \overline{\text{TPG}}_{\text{max}}}{\rho(1 - \text{GOA}^2/A_{\text{LVOT}}^2)}} \quad (3)$$

where A_{LVOT} is the upstream (LVOT) cross-sectional area and ρ is the blood density. Mean $\overline{\text{TPG}}_{\text{max}}$ can be written as a function of EOA and mean squared actual flow rate ($\overline{Q^2}$), by means of the Bernoulli equation and the mass conservation, as follows (18):

$$\overline{\text{TPG}}_{\text{max}} = \frac{1}{2} \rho \overline{Q^2} \left(\frac{1}{\text{EOA}^2} - \frac{1}{A_{\text{LVOT}}^2} \right) \quad (4)$$

The combination of Eqns. (2), (3), and (4) yields the relationship between C_D and C_C :

$$C_D = C_C \sqrt{\frac{1 - \text{GOA}^2/A_{\text{LVOT}}^2}{1 - C_C^2 \text{GOA}^2/A_{\text{LVOT}}^2}} \quad (5)$$

From this expression it clearly appears that C_D and C_C are generally not equal since C_D depends not only on C_C but also on the $\text{GOA}/A_{\text{LVOT}}$ ratio. C_D , however, tends to become equal to C_C for small values of $\text{GOA}/A_{\text{LVOT}}$ ($<1/4$), and therefore for severe stenosis. In conclusion, whereas the definitions of C_C and C_D are based on two different physical concepts, their respective numerical values are almost equal in the particular case of severe aortic stenosis. This likely explains why they were used interchangeably in some in-vitro and in-vivo studies. Because their definitions and numerical values differ between mild and moderate stenosis, the term 'discharge coefficient' should not be used when referring to the EOA/GOA ratio which is, by definition, the contraction coefficient, C_C .

GOA, EOA and C_C

As mentioned previously, GOA represents the geometric area of the valve orifice, whereas EOA is the minimal cross-sectional area of the downstream jet (Fig. 3): hence, GOA can be measured with a ruler, while EOA cannot. The relationship between EOA and GOA, and therefore the value of C_C ($= \text{EOA}/\text{GOA}$), is highly dependent upon the valve inflow shape (11,19). In particular, C_C may vary significantly with the valve aperture angle for a given flow rate. This dependence may be found in aortic stenosis with stiffened valve leaflets, and can be expressed analytically using the theory of flow jets in an ideal fluid as (20):

$$C_C(\theta) = \pi \left[\pi + \int_0^\pi \cot\left(\frac{\sigma}{2}\right) \sin\left(\frac{\theta - \sigma}{\pi}\right) d\sigma \right]^{-1} \quad (6)$$

Figure 4 depicts the variation of C_C , given by Eqn. (6), with the aperture angle θ . Note that when θ is zero - that is, when the valve is fully open - C_C is equal to 1 and thus $\text{EOA} = \text{GOA}$. In contrast, when θ is $\pi/2$ ($= 90^\circ$), as might be encountered in a severely calcified and totally rigid aortic stenosis, C_C is equal to $\pi/(\pi+2) \approx 0.61$. For a normal aortic valve or a funnel-shaped aortic stenosis, the streamlines do not continue to converge downstream of the tips of the valve leaflets (Fig. 3B). Thus, EOA is equal to GOA and therefore $C_C = 1$, as reported in vitro and in vivo by some investigators (11,12,19,21). This shows that in some particular aortic stenoses (e.g., funnel-shaped), GOA may be equivalent to EOA. In most cases, however, C_C is <1 in patients with aortic stenosis and could, in theory, be as small as

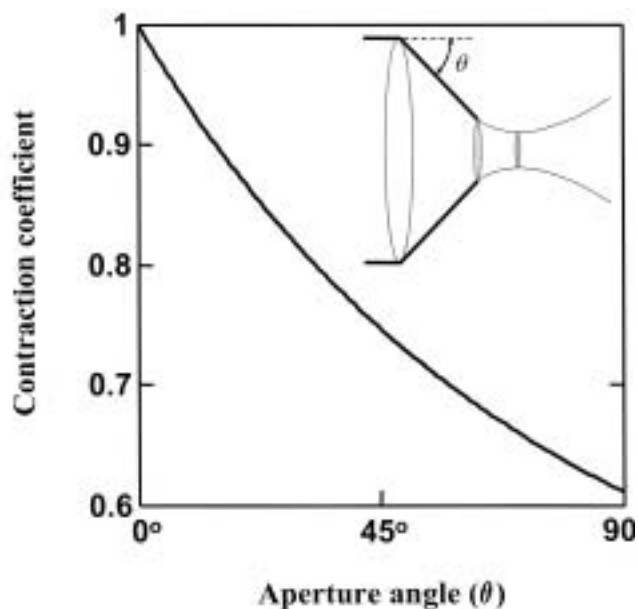


Figure 4: Variation of the contraction coefficient (C_c) as a function of the aperture angle (θ) for a rigid sharp-edged aortic stenosis as represented in Figure 3A.

0.6, so that GOA and EOA are generally significantly different (11,12). For example, in the study conducted by Gilon et al. (11), C_c was significantly lower for flat compared to doming bicuspid valves (0.73 ± 0.14 versus 0.94 ± 0.14 cm²) in patients with aortic stenosis. De La Fuente Galan et al. (12) also reported C_c values of 1.11 ± 0.28 in patients with mildly or moderately calcified aortic stenosis, and values of 0.79 ± 0.28 in patients with severely calcified valves. [Note that C_c is >1 in the report of De La Fuente Galan et al. (12) due to measurement errors inherent in echocardiography.] In other words, GOA is almost equal to EOA in mildly calcified aortic stenosis, but significantly greater in severely calcified aortic stenosis (Table I). Consequently, it is clear that planimetry cannot be used as a substitute for Doppler echocardiography to estimate EOA, since C_c is highly dependent upon aortic valve inflow configuration and is a priori unpredictable. In a recent study (22,23), it was shown that EOA might also be affected

by transvalvular flow rate if EOA was >0.9 cm², and more particularly for low flow rates (cardiac output <2.1 l/min). The variation of EOA with flow is essentially related to the preponderance of inertial forces due to flow unsteadiness (as estimated by the Strouhal number) for such a flow regime. It was also shown possible to predict this EOA flow dependence accurately when considering these unsteady effects at low flow rates. The flow can, however, be considered as quasi-steady at normal to high cardiac output with moderate to severe aortic stenosis (24), so that inertial effects due to unsteadiness are negligible and EOA becomes quasi-independent of the mean flow rate for a given aortic valve geometry (19,23).

Doppler EOA versus Gorlin area

Cardiac catheterization and Doppler echocardiography are the two standard methods used to measure AVA to assess the severity of aortic stenosis. Although some investigators have found a good agreement between these two methods, others have reported important discrepancies (4,13,14,25). In the latter studies, catheter AVA was usually higher than Doppler AVA. Catheter AVA is determined using the Gorlin formula, whereas Doppler AVA is determined with the continuity equation and measures the EOA. The continuity equation states that the flow rate in the LVOT equals that in the vena contracta (VC) - that is, $EOA VTI_{VC} = A_{LVOT} VTI_{LVOT}$, where VTI_{VC} is the velocity time integral at the level of the vena contracta measured by continuous-wave Doppler and VTI_{LVOT} is the subvalvular velocity time integral measured by pulsed-wave Doppler. EOA - that is, the cross-sectional area of the jet at the level of the vena contracta (Fig. 2) - is therefore written as:

$$EOA = \frac{A_{LVOT} VTI_{LVOT}}{VTI_{VC}} = \frac{SV}{VTI_{VC}} \quad (7)$$

where SV is the stroke volume. Measurement of AVA by catheterization is based on the Bernoulli equation, which describes the conservation of flow energy,

Table I: Comparison between Doppler EOA and echocardiographic GOA in 24 patients with mild/moderate or severe calcified aortic stenosis.*

Degree of calcification	No. of patients	EOA	GOA	p-value
Mild/moderate	10	0.72 ± 0.16	0.66 ± 0.15	0.23
Severe	14	0.54 ± 0.09	0.77 ± 0.27	0.0052

*Data taken from the study of de la Fuente Galan et al. (12).

A paired *t*-test was performed to compare GOA with EOA in the two groups.

Note that GOA differs significantly from EOA in the severely calcified group ($p < 0.01$).

applied between the LVOT and the vena contracta. The resulting Gorlin formula yields the Gorlin area, written as a function of the mean systolic flow rate (Q) and the mean transvalvular pressure gradient (TPG). When applying standard clinical units (cm², mmHg and ml/s), the Gorlin area is written as:

$$\text{Gorlin area} = \frac{Q}{50\sqrt{\text{TPG}}} \quad (8)$$

In theory, if TPG were to be calculated from pressure measurements within the vena contracta, then it would be equal to TPG_{max} and the Gorlin area would in turn be equal to the Doppler EOA (13). In this hypothetical case, the Gorlin area would thus reflect the minimal cross-sectional area of the flow jet. However, it is difficult to measure TPG_{max} by catheterization because of the difficulty in obtaining adequate pressure acquisitions within the vena contracta. Therefore, the catheter tip is generally positioned a few centimeters downstream of the vena contracta, which thus provides the TPG_{net} (TPG_{net} < TPG_{max}) (Fig. 2). From the energy loss concept, it can be demonstrated that the Gorlin area may be written as (13):

$$\text{Gorlin area} = \frac{\text{EOA } A_A}{A_A - \text{EOA}} \quad (9)$$

Thus, the Gorlin area depends not only on the EOA but also on the aortic cross-sectional area measured at the sinotubular junction (A_A). Hence, Eqn. (9) can be rewritten as:

$$\frac{\text{EOA}}{\text{Gorlin area}} = 1 - \frac{\text{EOA}}{A_A} \quad (10)$$

Equation (10) shows that EOA is systematically smaller than the Gorlin area, which means that Doppler echocardiography overestimates aortic stenosis severity when compared to catheterization. This is consistent with in-vivo studies performed in patients with aortic stenosis (13,25,26). Thus, clinicians should be aware that Doppler echocardiography and catheterization may lead to different AVA values, and all the more so when the aortic diameter is relatively small (14).

Doppler echocardiography provides the lowest AVA value

As discussed above, AVA may reflect the EOA, Gorlin area or anatomic area (GOA), depending on the technique used to assess stenosis severity (Table II). The differences between these three AVA values depend mainly on the valve inflow shape and the cross-sectional area of the ascending aorta: the discrepancy between Doppler echocardiography and catheterization is mostly related to the aortic cross-sectional area (see Eqn. (11)), whereas the difference between Doppler echocardiography and planimetry is essentially dependent upon the valve geometry (see Eqn. (7)). Because these anatomic characteristics vary significantly from one patient to another, the relationship between EOA, Gorlin area and GOA is highly patient-specific. According to the American College of Cardiology/American Heart Association (ACC/AHA) recommendations (2), an aortic stenosis is graded as mild when AVA is >1.5 cm², moderate if AVA is >1.0-1.5 cm², or severe if AVA is ≤1.0 cm². Based on these criteria, Doppler echocardiography, planimetry or catheterization may lead to contradictory diagnoses. Assuming that there are no measurement errors due to technical limitations, Doppler echocardiography in theory provides the smallest AVA value and thus the greatest severity of aortic stenosis. Many investigators have consistently reported that the Doppler EOA is systematically smaller than Gorlin area in patients with aortic stenosis (4,13,21,25). In the latter studies, the difference between Doppler EOA and Gorlin area was more obvious with moderate aortic stenosis (25) or small aorta (13), as predicted by Eqn. (11). Others have also shown that Doppler EOA is always smaller than planimetry AVA (GOA) with highly calcified or flattened aortic stenosis (11,12). In this case, the EOA on GOA ratio (i.e., C_C) was as low as 0.7 (11,12) which means that planimetry overestimated Doppler echocardiography by more than 40%. The same studies showed, however, that planimetry and Doppler echocardiography produced identical results with non-calcified or mildly calcified valves. Based on the above-mentioned findings, the ways in which AVA may significantly vary depending on the diagnostic method applied are summarized in Table III. In this illustration, while planimetry AVA

Table II: Diagnostic methods used to assess aortic stenosis severity and their corresponding aortic valve area (AVA).

Diagnostic method	AVA	Definition
Echocardiographic or CMR planimetry	GOA	Anatomic area of the valve aperture
Doppler echocardiography	EOA	Cross-sectional area of the vena contracta
Cardiac catheterization	EOA A _A /(A _A - EOA)	Area characterizing the flow energy loss

A_A: Aortic cross-sectional area; CMR: Cardiac magnetic resonance; EOA: Effective orifice area; GOA: Geometric orifice area.

(GOA) is fixed at 1.0 cm² for each stenosis geometry, Doppler AVA (EOA) and catheter AVA (Gorlin area) could range from 0.6 to 1.5 cm². Thus, the data in Table III clearly show that AVA measurements may lead to different estimations of stenosis severity, depending on the measurement method and the valvular and aortic geometries. As an example, with a severely calcified aortic stenosis as depicted in Table III (left column), the stenosis would be graded as moderate (AVA = 1.0 cm²) by planimetry, but severe (AVA = 0.6 cm²) by Doppler echocardiography. In this context, it should be emphasized that the ACC/AHA guidelines for assessing aortic stenosis severity were mainly based on data obtained from catheterization. The same AVA values for aortic stenosis severity were then extended to Doppler or planimetry on the assumption that Doppler EOA and planimetric GOA were similar to Gorlin area. This would only be possible in the very specific condition of a relatively large ascending aorta (i.e., small EOA on A_A ratio) and a mild calcified aortic stenosis (Fig. 5). The above-mentioned guidelines make no distinction, however, between these three measurement methods. One may therefore wonder which AVA better reflects the severity of aortic stenosis.

Which AVA is the most reliable from a clinical standpoint?

It was shown recently (27) that the energy loss caused by aortic stenosis is reflected by what is termed the “energy loss coefficient” (E_LCo), which has the dimension of an area (cm²). E_LCo is measurable by Doppler and expressed as a function of EOA. Importantly, it also takes into account the aortic area at the sinotubular junction (A_A), as follows:

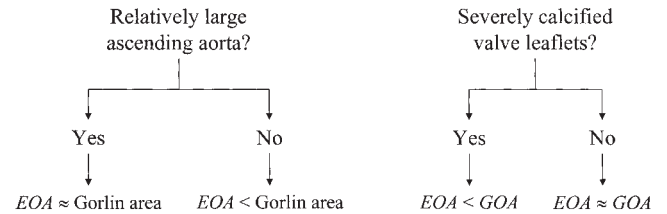


Figure 5: Relationship between EOA and Gorlin area and between EOA and GOA in different physiological contexts.

$$E_LCo = \frac{EOA A_A}{A_A - EOA} \tag{12}$$

When comparing Eqn. (11) to Eqn. (9), it is clear that the Gorlin area is equal to E_LCo. Thus, Doppler echocardiography can be reconciled with catheterization if measuring E_LCo by means of Eqn. (11). In a recent study of 138 patients with moderate or severe aortic stenosis, Doppler E_LCo was shown to reflect the severity of aortic stenosis better than Doppler EOA (27). It was then verified, both in animals and in patients (13,14), that Doppler E_LCo and Gorlin area were identical parameters. When E_LCo was indexed for body surface area, a cut-off value of 0.52 cm²/m² was also found to be the best predictor of adverse outcome of aortic stenosis (27). From a hemodynamic standpoint, Doppler E_LCo and Gorlin area both reflect the net energy loss induced by the aortic stenosis, and are therefore more representative of the increased workload imposed on the left ventricle, compared to GOA and EOA. On the other hand, GOA does not characterize the flow property; it reflects solely the area of the valve anatomic orifice. Indeed, as mentioned previously, there are many different inflow jet configurations for a given GOA. As a consequence, the

Table III: Gorlin area and effective orifice area (EOA) for different geometries of aortic stenosis when geometric orifice area (GOA) is fixed at 1.0 cm².

Method used	Geometry of aortic stenosis		
Planimetry GOA (cm ²)	1.0	1.0	1.0
Doppler EOA (cm ²)	0.6	0.75	1.0
Catheterization Gorlin area (cm ²) (A _A = 7 cm ²)	0.65	0.85	1.15
Catheterization Gorlin area (cm ²) (A _A = 3 cm ²)	0.75	1.0	1.5

Eqns. (6) and (9) were used to complete this table.
 AA: Aortic cross-sectional area.

relationship between GOA and EOA (i.e., C_c) is highly dependent upon the degree of valvular calcification and may therefore vary extensively from one patient to another (see Tables I and III). Furthermore, the EOA is not adequate for the accurate assessment of true energy losses caused by the stenosis because it does not take into account the pressure recovery occurring downstream of the vena contracta. As stated by Eqn. (11), the energy loss is influenced not only by EOA but also by the aortic cross-sectional area. The E_LCo represents one means of adjusting the EOA for the size of the aorta in order to take into account the pressure recovery and thus better assess the net energy loss induced by the stenosis. Hence, it would be preferable to use the E_LCo as the echocardiographic parameter to assess the severity of aortic stenosis. In this case, the severity criteria proposed in the ACC/AHA guidelines would become directly applicable (2). The E_LCo measured by Doppler echocardiography and the Gorlin area measured by catheterization are two equivalent parameters that reflect the true energy loss caused by the stenosis. Nonetheless, advice has been recently given not to perform retrograde catheterization in aortic stenosis unless additional information is necessary for clinical management (28). Indeed, retrograde catheterization has been associated with a substantial risk of clinically apparent cerebral embolism in patients with aortic stenosis (29). Because it is now possible to predict the Gorlin area accurately by calculating E_LCo from the Doppler-echocardiographic examination, it is the present authors' opinion that retrograde catheterization to assess aortic stenosis severity should be considered only in patients with unclear echocardiographic findings (28,29).

In conclusion, when assessing the severity of aortic stenosis, GOA, EOA and Gorlin area represent different hemodynamic parameters, and the differences among them are highly dependent upon the valve inflow shape and aortic cross-sectional area. Thus, it is important that investigators indicate to which parameter they are referring when using the term "aortic valve area". Because echocardiographic or cardiac magnetic resonance planimetry provides only the GOA, this method should preferably not be used to assess stenosis severity. The most appropriate parameters for this purpose are the Gorlin area or the E_LCo , which correspond to the EOA adjusted for aortic cross-sectional area. Although the Gorlin area and the E_LCo are equivalent from a hemodynamic standpoint, the latter parameter has the advantage of being measurable non-invasively by Doppler echocardiography.

Acknowledgements

The authors are indebted to Dr. Philippe Pibarot (Quebec Heart Institute, Sainte-Foy, QC) for his very helpful suggestions, and to Dr. Lysanne Goyer (Clinical Research Institute of Montreal, Montréal, QC) for having reviewed the manuscript.

References

1. Baumgartner H. Aortic stenosis: Medical and surgical management. *Heart* 2005;91:1483-1488
2. Bonow RO, Carabello B, De Leon AC, et al. Guidelines for the management of patients with valvular heart disease: Executive summary. A report of the American College of Cardiology/American Heart Association Task Force on Practice Guidelines (Committee on Management of Patients with Valvular Heart Disease). *Circulation* 1998;98:1949-1984
3. Shavelle DM, Otto CM. Aortic stenosis. In: Crawford MH, Dimarco JP (ed.), *Cardiology*. Mosby, London, 2000:9.1-9.9
4. Oh JK, Taliario CP, Holmes DR, Jr., et al. Prediction of the severity of aortic stenosis by Doppler aortic valve area determination: Prospective Doppler-catheterization correlation in 100 patients. *J Am Coll Cardiol* 1988;11:1227-1234
5. Okura H, Yoshida K, Hozumi T, Akasaka T, Yoshikawa J. Planimetry and transthoracic two-dimensional echocardiography in noninvasive assessment of aortic valve area in patients with valvular aortic stenosis. *J Am Coll Cardiol* 1997;30:753-759
6. Ge S, Warner JG, Jr., Abraham TP, et al. Three-dimensional surface area of the aortic valve orifice by three-dimensional echocardiography: Clinical validation of a novel index for assessment of aortic stenosis. *Am Heart J* 1998;136:1042-1050
7. John AS, Dill T, Brandt RR, et al. Magnetic resonance to assess the aortic valve area in aortic stenosis: How does it compare to current diagnostic standards? *J Am Coll Cardiol* 2003;42:519-526
8. Kupfahl C, Honold M, Meinhardt G, et al. Evaluation of aortic stenosis by cardiovascular magnetic resonance imaging: Comparison with established routine clinical techniques. *Heart* 2004;90:893-901
9. Debl K, Djavidani B, Seitz J, et al. Planimetry of aortic valve area in aortic stenosis by magnetic resonance imaging. *Invest Radiol* 2005;40:631-636
10. Feuchtner GM, Dichtl W, Friedrich GJ, et al. Multislice computed tomography for detection of patients with aortic valve stenosis and quantification of severity. *J Am Coll Cardiol* 2006;47:1410-1417

11. Gilon D, Cape EG, Handschumacher MD, et al. Effect of three-dimensional valve shape on the hemodynamics of aortic stenosis: Three-dimensional echocardiographic stereolithography and patient studies. *J Am Coll Cardiol* 2002;40:1479-1486
12. De La Fuente Galan L, Roman Calvar JA, Munoz San Jose JC, et al. [Influence of the degree of aortic valve calcification on the estimate of valvular area using planimetry with transesophageal echocardiography]. *Rev Esp Cardiol* 1996;49:663-668
13. Garcia D, Dumesnil JG, Durand LG, Kadem L, Pibarot P. Discrepancies between catheter and Doppler estimates of valve effective orifice area can be predicted from the pressure recovery phenomenon: Practical implications with regard to quantification of aortic stenosis severity. *J Am Coll Cardiol* 2003;41:435-442
14. Levine RA, Schwammenthal E. Stenosis is in the eye of the observer: Impact of pressure recovery on assessing aortic valve area. *J Am Coll Cardiol* 2003;41:443-445
15. Weyman AE, Scherrer-Crosbie M. Aortic stenosis: Physics and physiology - what do the numbers really mean? *Rev Cardiovasc Med* 2005;6:23-32
16. Baumgartner H, Stefenelli T, Niederberger J, Schima H, Maurer G. 'Overestimation' of catheter gradients by Doppler ultrasound in patients with aortic stenosis: A predictable manifestation of pressure recovery. *J Am Coll Cardiol* 1999;33:1655-1661
17. Munson BR, Young DF, Okiishi TH. Viscous flow in pipes. In: *Fundamentals of fluid mechanics*. Second edition. John Wiley & Sons, Inc., New York, 1994:455-547
18. Garcia D, Kadem L, Savery D, Pibarot P, Durand LG. Analytical modeling of the instantaneous maximal transvalvular pressure gradient in aortic stenosis. *J Biomech* 2006;doi:10.1016/j.jbiomech.2005.10.013.
19. Garcia D, Pibarot P, Landry C, et al. Estimation of aortic valve effective orifice area by Doppler echocardiography: Effects of valve inflow shape and flow rate. *J Am Soc Echocardiogr* 2004;17:756-765
20. Gurevich MI. *Theory of jets in ideal fluids*. Academic Press, New York, London, 1965
21. Chambers JB, Sprigings DC, Cochrane T, et al. Continuity equation and Gorlin formula compared with directly observed orifice area in native and prosthetic aortic valves. *Br Heart J* 1992;67:193-199
22. Baumgartner H. Hemodynamic assessment of aortic stenosis. Are there still lessons to learn? *J Am Coll Cardiol* 2006;47:138-140
23. Kadem L, Rieu R, Dumesnil JG, Durand LG, Pibarot P. Flow-dependent changes in Doppler-derived aortic valve effective orifice area are real and not due to artefact. *J Am Coll Cardiol* 2006;47:131-137
24. Clark C. The fluid mechanics of aortic stenosis - II. Unsteady flow experiments. *J Biomech* 1976;9:567-573
25. Danielsen R, Nordrehaug JE, Vik-Mo H. Factors affecting Doppler echocardiographic valve area assessment in aortic stenosis. *Am J Cardiol* 1989;63:1107-1111
26. Schobel WA, Voelker W, Haase KK, Karsch KR. Extent, determinants and clinical importance of pressure recovery in patients with aortic valve stenosis. *Eur Heart J* 1999;20:1355-1363
27. Garcia D, Pibarot P, Dumesnil JG, Sakr F, Durand LG. Assessment of aortic valve stenosis severity: A new index based on the energy loss concept. *Circulation* 2000;101:765-771
28. Chambers J, Bach D, Dumesnil JG, Otto CM, Shah P, Thomas J. Crossing the aortic valve in severe aortic stenosis: No longer acceptable? *J Heart Valve Dis* 2004;13:344-346
29. Omran H, Schmidt H, Hackenbroch M, et al. Silent and apparent cerebral embolism after retrograde catheterisation of the aortic valve in valvular stenosis: A prospective, randomised study. *Lancet* 2003;361:1241-1246